Liver flukes: Fascioliasis Clinical manifestations

Dr Afshin Shafaghi M.D.
Professor of Gastroenterology-Hepatology , G.U.M.S

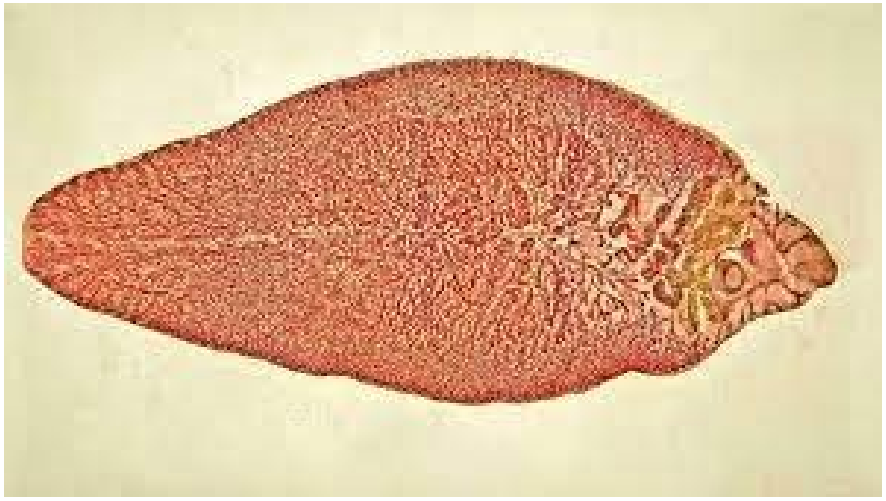

Clinical manifestations

- Many infections are mild, it is estimated that about 50 percent of cases are asymptomatic ; morbidity increases with fluke burden . Forms of infection include :
- 1-Acute (liver) phase
- 2- Chronic (biliary) phase
- 3- Ectopic Fascioliasis,
- 4- Pharyngeal Fascioliasis.

Acute (liver) phase

- Acute symptoms usually begin within 6 to 12 weeks of metacercariae ingestion. The early phase of migration through the liver is often associated with fever, right upper quadrant pain, and hepatomegaly. Jaundice is occasionally observed .

- Other symptoms include anorexia, nausea, vomiting, weight loss, myalgia, cough, and urticaria.

- Marked peripheral eosinophilia is almost always present. The acute phase can be complicated by hemobilia or subcapsular hematomas of the liver

- In most cases, acute symptoms generally resolve after about six weeks, although, in very heavy infections, extensive liver parenchymal necrosis can result.

Acute (liver) phase

- Extrahepatic symptoms may also occur during the acute phase, likely related to an immunologic or allergic mechanism.

- A Loeffler-like syndrome or right-sided pleural effusion containing many eosinophils may be observed

- The urticaria may be associated with pruritus and dermatographia . Pericarditis, cardiac conduction abnormalities, meningeal symptoms, focal neurologic changes, or seizures have also been described but are uncommon.

Chronic (biliary) phase

- The chronic phase usually begins about six months after infection and may last 10 years or more . This phase is usually asymptomatic, although epigastric and right upper quadrant pain, diarrhea, nausea, vomiting, wasting, hepatomegaly, and jaundice can occur.

- Common bile duct obstruction can develop, and chronic infection can lead to biliary colic, cholangitis, cholelithiasis, and obstructive jaundice.

- Secondary pancreatitis has been reported in up to 30 percent of cases. Parasite eggs or adult worms may serve as a nidus for stone formation, leading to intra- or extrahepatic biliary lithiasis.

- Prolonged and/or heavy infection can also result in sclerosing cholangitis and biliary cirrhosis. Peripheral eosinophilia may or may not be present in the biliary phase.

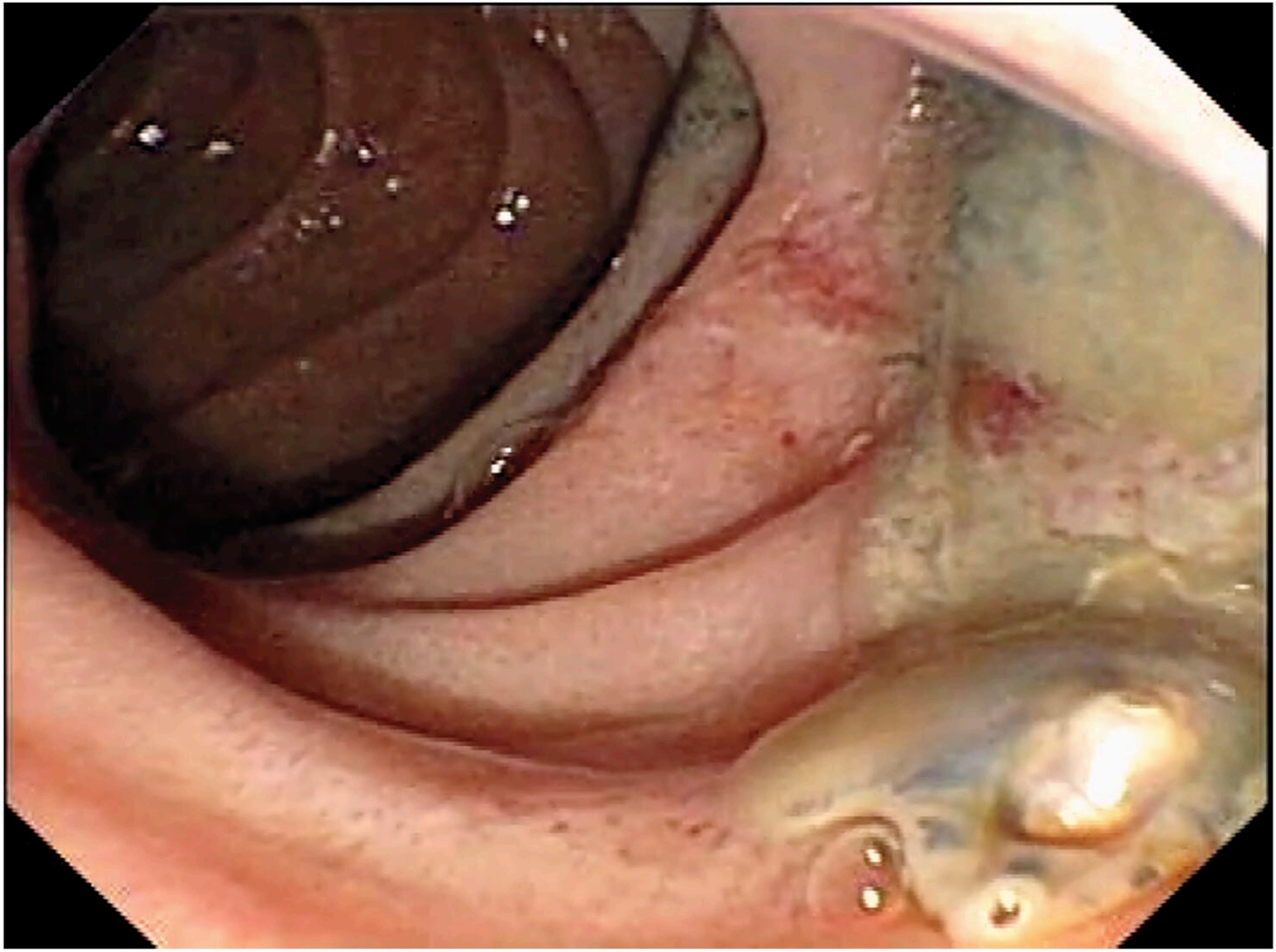

ANNALS of Hepatology

CASE REPORT

May-June, Vol. 11 No.3, 2012: 395-398

Living *Fasciola hepatica* in biliary tree: a case report

Keyvan Aminian,* Kambiz Akhavan Rezayat,* Afshin Shafaghi,* Roozbeh Tanhaeevash**

* Department of Gastroenterology, Razi Hospital, Guilan University of Medical sciences, Rasht, Iran.** Farzan Clinical Research, Tehran, Iran.

ABSTRACT

Here we report a rare case of living *Fasciola hepatica* in biliary tract. The patient was in acute phase of infection and treated successfully with 10 mg/kg oral triclabendazole after the fluke was extracted using endoscopic retrograde cholangiopancreatography (ERCP).

Key words. Fasciola hepatica. Biliary tree.

INTRODUCTION

Fascioliasis is a parasitic infection caused by *Fasciola hepatica (F. hepatica)* fluke worm which affects more than three millions of people worldwide.[1] It occurs more frequently in some parts of Latin America, Eastern Europe, Far and Middle East (e.g. northern Iran) and can result in biliary tract obstruction, cholangitis, cholecystitis as well as pancreatitis and anemia.[2-4]

Humans may be accidental hosts of *F. hepatica* by ingestion of metacercariae during consumption of contaminated water or raw vegetables. In humans, maturation of metacercaria into adult fluke takes approximately 3 to 4 months (Figure 1). However, it is very rare to find a living fluke in the common bile duct (CBD) as it usually lives in gall-bladder and smaller biliary tracts.[5]

Herein we report a case of living *F. hepatica* in biliary tract without hepatobiliary damage that was found by endoscopic retrograde cholangiopancreatoper quadrant (RUQ) abdominal pain for the last two weeks. There were no other symptoms like anorexia, weight loss, nausea, vomiting, cough, diarrhea, jaundice, urticaria, pruritus and arthralgia. On physical examination, mild RUQ tenderness and normal liver span were noticed.

In addition, laboratory findings revealed mild leukocytosis (WBC: 10,600/mm^3) with remarkable eosinophilia (25%). Serum bilirubin, gamma-glutamyl transpeptidase (GGT), aspartate aminotransferase (AST), alanine aminotransferase (ALT) and alkaline phosphatase (ALP) were within normal limits.

Ultrasonographic findings denoted normal hepatic parenchyma with dilated CBD. In ERCP, multiple irregular filling defects, some of which floating, were detected in the dilated CBD. After sphincterotomy and balloon extraction, a live fluke *(F. hepatica)* with some fragmented particles, suggestive of eggs, were detected in hepatopancreatic ampulla (Figure 2). The diagnosis was confirmed by increased titer of anti-*Fasciola hepatica* antibody.[6]

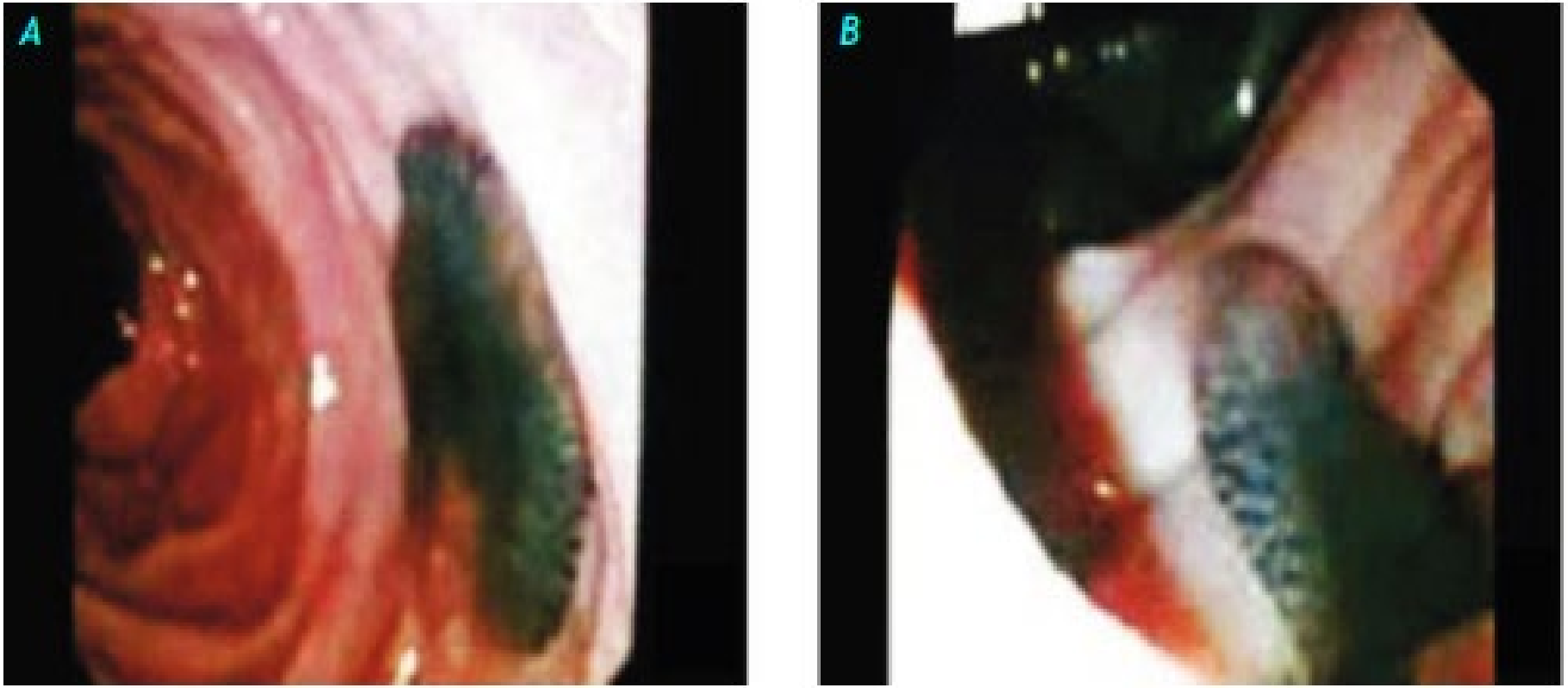
A
B

Ectopic Fascioliasis

- Extrahepatic involvement may occur; it is unknown whether the parasites migrate to ectopic sites hematogenously or through soft tissues.
- The most common ectopic site is the subcutaneous tissue of the abdominal wall. The lungs, heart, brain, muscle, GU tract, and the eye may also be affected
- Tender, migrating, erythematous, itchy nodules (1 to 6 cm in diameter) can develop; in some cases, these may result in localized abscesses. Generalized lymphadenopathy may also develop .





Cerebral manifestations include space occupying lesions, cerebral infarction, and hemorrhage (intracerebral, subdural, or subarachnoid

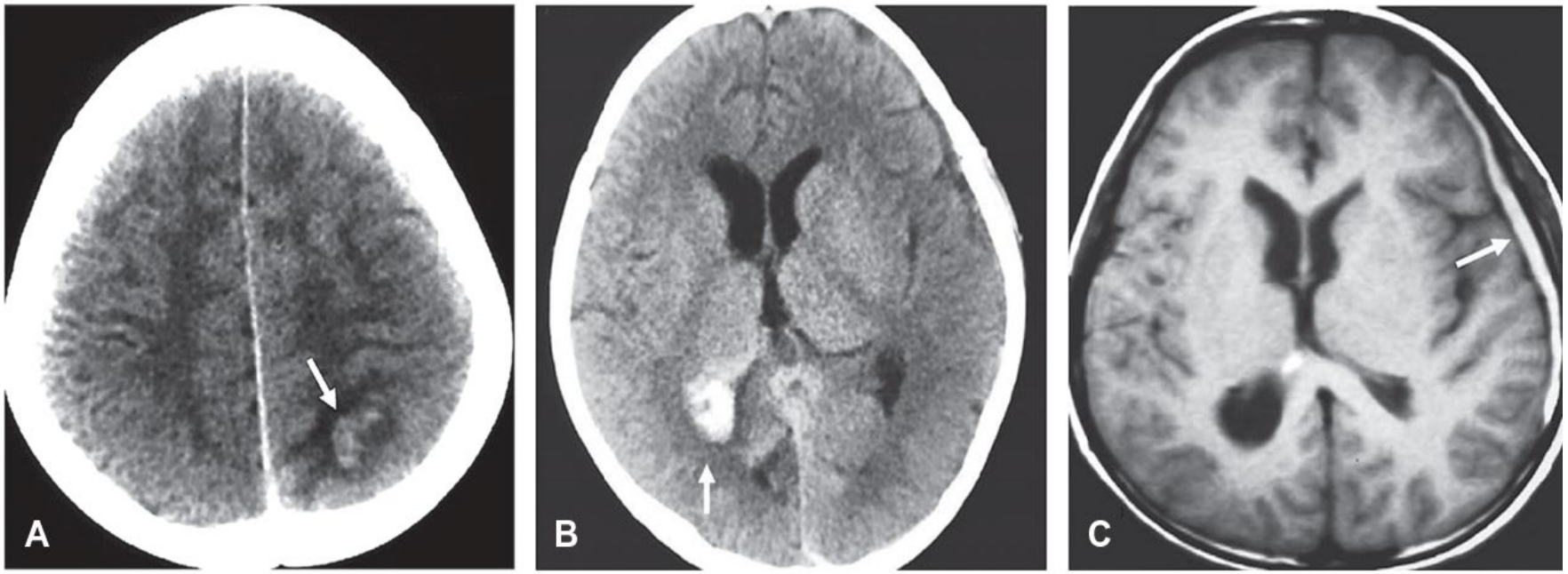

- Varying brain lesions (arrows) caused by a migrating small immature Fasciola hepatica juvenile observed by CT and MRI in a 10-year-old boy from China affected by five consecutive episodes of intracranial hemorrhages and hematomas: (A) head CT scan on the third hospital day showing cerebral hemorrhage (third hemorrhage) in the left parietal lobe; (B) a repeated head CT performed on the 11th hospital day showing a new hematoma (fourth hematoma) in the right lateral ventricle; (C) head MRI performed on the 20th hospital day showing a new subdural hematoma (fifth hematoma) in the left fronto-temporo-parieto-occipital lobe.

Pharyngeal Fascioliasis

- Pharyngeal fascioliasis is a form of fascioliasis that occurs in the Middle East; it is acquired by consumption of raw liver of an infected animal. The living fluke can attach to the upper respiratory or digestive tract, causing an **allergic pharyngitis** with edema and congestion; suffocation may result.

- This condition is also known as **'Halzoun syndrome.'** The syndrome was first described in **Lebanon** in 1905 and initially attributed to Fasciola hepatica; subsequent publications have also attributed it to other pathogens including Dicrocoelium dendriticum and Linguatula serrata

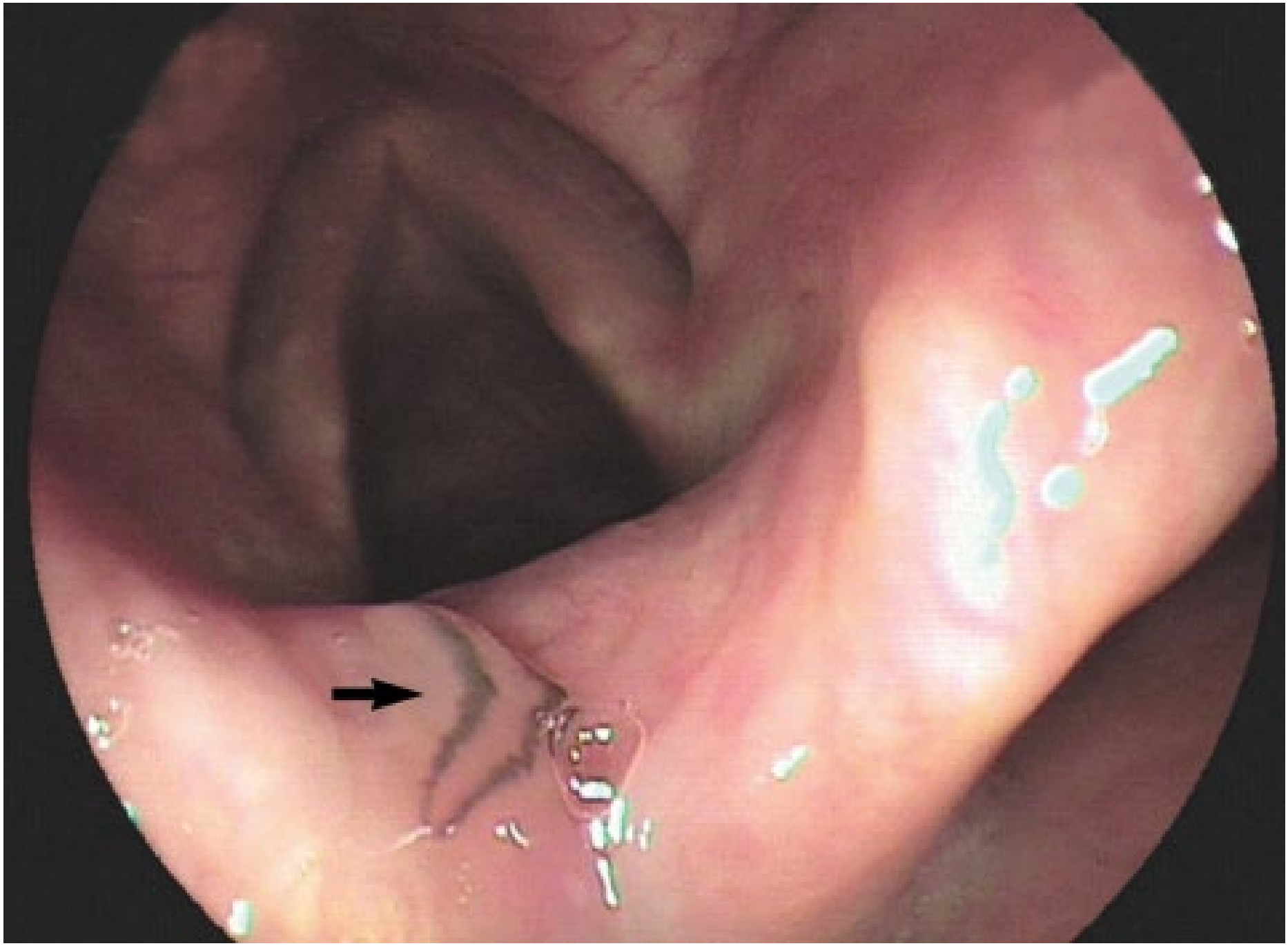

Strongyloidiasis

CLINICAL MANIFESTATIONS

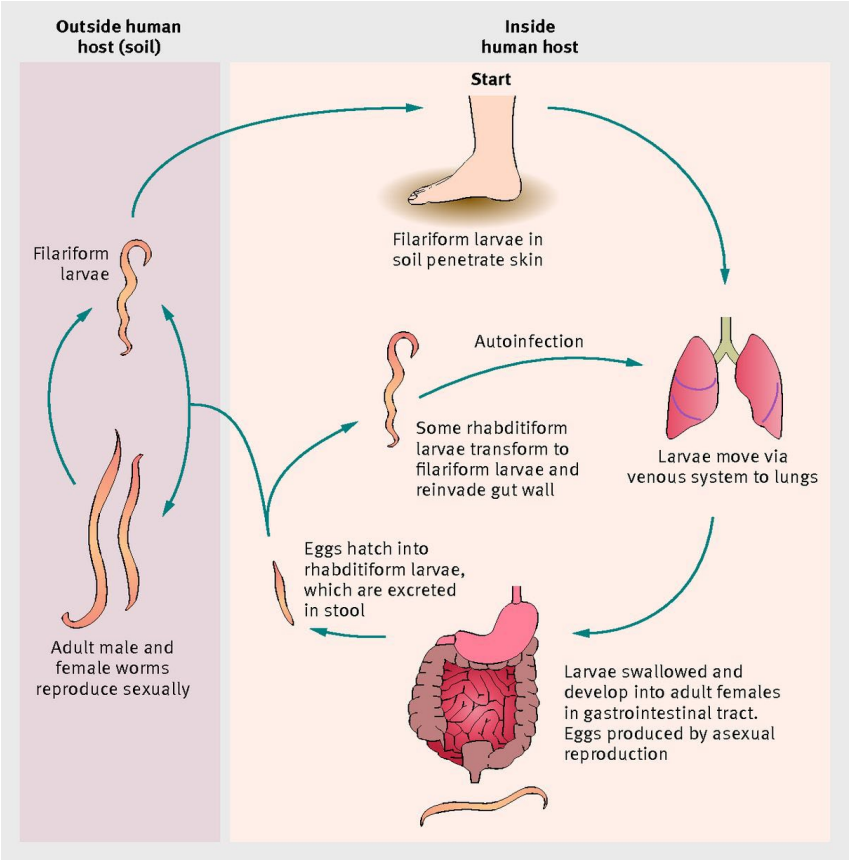

Symptoms

- Most *Strongyloides* infections are asymptomatic and can survive decades undiagnosed
  - The longest documented asymptomatic infection was more than 65 years
- Symptomatic infections typically manifest in gastrointestinal, pulmonary, and dermatologic systems
- In immunocompromised persons, symptomatic infections can be devastating and carry a 60-85% mortality rate
- Acute Infection
- Chronic infection
- Hyperinfection
- Disseminated Infection



Acute infection

- The clinical manifestations of acute strongyloidiasis reflect the path of larval migration from the site of skin penetration to the small intestine, where new adults will develop and start producing larvae. Clinical manifestations during larval penetrations are rarely recognized and reported.



- Within a week following transmission, a dry cough may develop.

- Following the establishment of infection in the small intestine (as early as the third week following transmission), gastrointestinal (GI) symptoms such as diarrhea, constipation, abdominal pain, or anorexia may occur.

- Approximately one month following transmission, larval production by the newly established adult worms begins; new cycles of infection may be initiated via autoinfection (**either within the intestinal mucosa or the perianal skin**).

Strongyloidiasis often does not cause any symptoms. But it may cause:

- Burning upper abdominal pain.
- Cough.
- Diarrhea or constipation.
- Nausea or vomiting.
- Rash.
- Red, irritated skin near the anus.
- Weight loss.



Chronic infection

- **Gastrointestinal symptoms :** are usually mild. Abdominal pain may be periumbilical or mid-epigastric , the latter likely due to the duodenal localization of adult and larval parasites. Other symptoms may include diarrhea, constipation, intermittent vomiting, and borborygmi.

- **Dermatologic manifestations :** Dermatologic manifestations include **larva currens**, **pruritus**, **urticaria**, and **angioedema**.

- **Larva currens** ("running" larva) presents as raised, pink, pruritic, evanescent streaks along the lower trunk, thighs, and buttocks, resulting from migrating larvae through the subcutaneous tissues .

- Larva currens can progress approximately 1 cm in 5 minutes and 5 to 15 cm per hour. As the larvae move, they leave behind a thin red line that gradually fades to brown and disappears within 48 hours. While larva currens is **pathognomonic** for strongyloidiasis, it is **uncommon**



- Urticaria is more frequent may be the sole clinical manifestation of chronic strongyloidiasis .In one study from NewYork , 61.9 percent of patients experienced cutaneous manifestation (pruritus, urticaria, angioedema, and/or rash) and half of these experienced symptomatic improvement after treatment with ivermectin.



●**Respiratory symptoms** – Respiratory symptoms include dry cough, throat irritation, dyspnea, and wheezing. *Asthma that paradoxically worsens with corticosteroid use may occur* .

- While eosinophilia may be indicative of strongyloidiasis, the absence of eosinophilia does not exclude infection with strongyloides or other intestinal helminths .

Severe manifestations

1- Hyperinfection refers to accelerated autoinfection; signs and symptoms are attributable to increased larval migration within the organs normally involved in the autoinfection cycle, the GI tract, lungs, and skin.

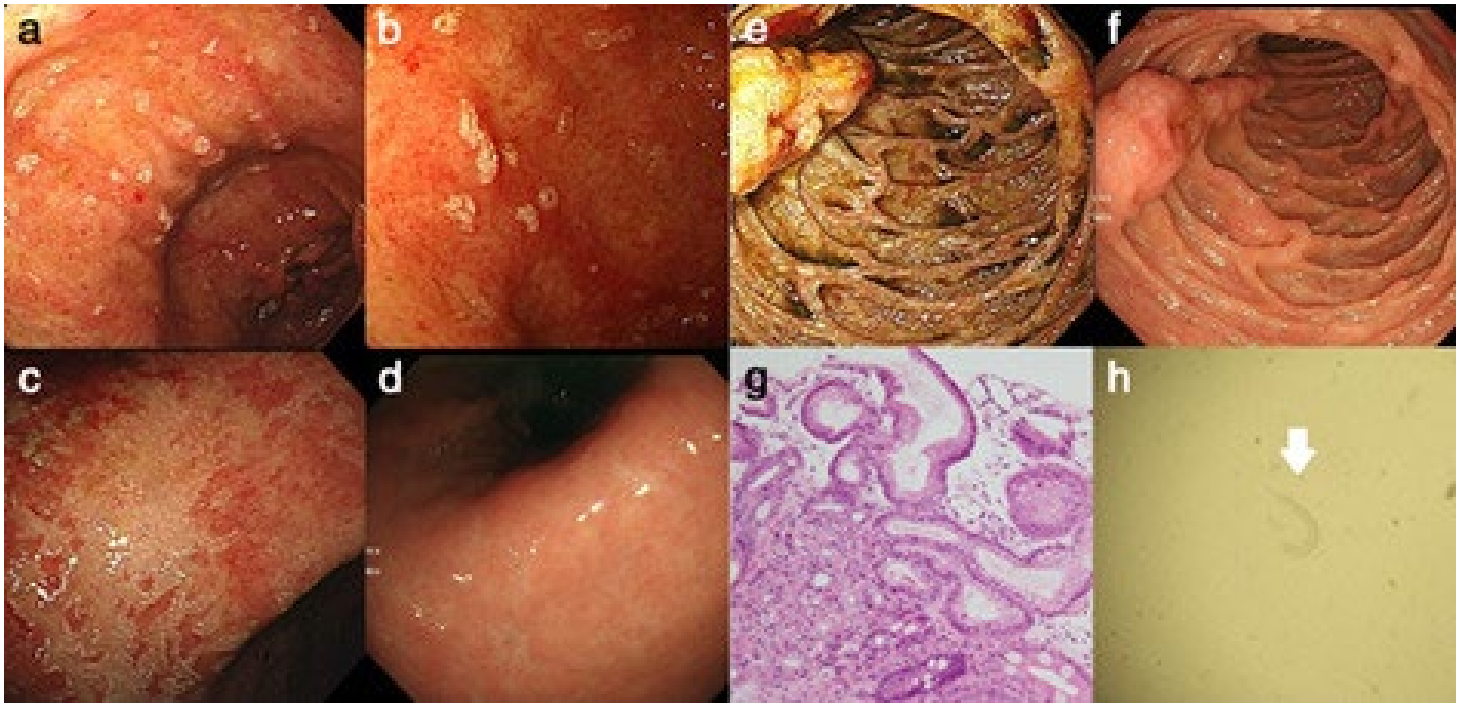

- **GI symptoms:** reflecting the presence of large quantities of larvae in the intestinal lumen; they are nonspecific and include abdominal pain (crampy or bloating in nature), watery diarrhea, constipation, anorexia, weight loss, difficulty swallowing, nausea, and vomiting. Electrolyte disturbances, inflammation, bleeding, ulceration, and small bowel obstruction may occur
- Fever and hemodynamic instability should prompt suspicion for **perforation**

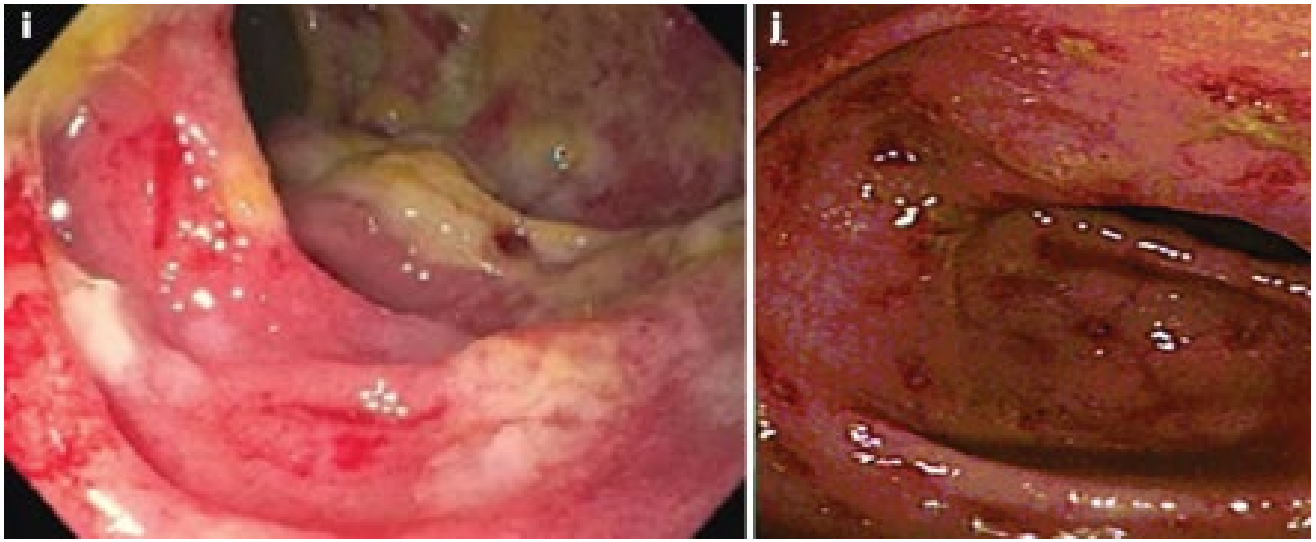

- Colitis and proctitis may be associated with occult or gross blood.
- Additional manifestations may include protein-losing enteropathy or ascites.



Medical Journal of the Islamic Republic of Iran. Vol. 22, No. 3, November, 2008. pp. 149-151

Significant weight loss, nausea, and vomiting due to strongyloidiasis: a case report

Hossein Froutan, MD,[1], Ayatollah Bayatian, MD.[2], Seied Mohsen Razavizadeh, MD.[3], Mohsen Nasiri-Toosi, MD.[4], Afshin Shafaghi, MD.[5]

Department of Internal Medicine, Imam Khomeini Hospital, Tehran, Iran.

Abstract

Strongyloidiasis is caused by infestation with Strongyloides stercoralis, a free living tropical and semitropical soil helminth that has a larval form that penetrates intact skin. Clinical manifestations may be varied from an asymptomatic infection in immunocompetent hosts to a diffuse and fatal form in immunocompromised hosts.

We report a 56-year-old man from Dezful (south-west of Iran) with a 6-month history of nausea, vomiting and significant weight loss (greater than 10%). Abdominal ultrasonography had no significant findings. Upper gastrointestinal series and abdominal CT were performed. Dilated bowel loops especially in the jejunum, with decreased mucosal folds were seen. A biopsy specimen from the third part of duodenum showed strongyloides larvae, thus albendazole 400 mg twice a day for 3 days was initiated. He responded well to this treatment regimen.

Keywords: strongyloidiasis, nausea, vomiting, albendazole.

Introduction

Strongyloidiasis is endemic in tropical and semitropical regions. Strongyloides exists as a free-living organism that does not require a host

al rash (larvae currens) caused by dermal migration of fillariform larvae and non-productive cough with or without hemoptysis [1] due to lung migration stage. Occasionally, patients have abdominal pain, anorexia, nausea, vomiting and diarrhea due to gastrointestinal involve-

nal symptoms are the usual presentation of this infection. Our patient presented not only with abdominal symptoms, but a significant loss of weight that may herald malignancies.

Case report

A 56 year old man from Dezful (south west of Iran) referred to our hospital with a 6 month history of bloating, epigastric and left lower quadrant pain, nausea and vomiting after eating. He had a significant loss of weight (18kg) (greater than 10% loss of his baseline body weight). He had a normal appetite. He had no history of diarrhea and melena. His abdominal pain did not correlate with body position. He had a history of pelvic fracture due to trauma and minor thalassemia. The patient was cachectic with a pale appearance. Vital signs were normal. Lung and heart exams were normal. The abdomen was soft with normal bowel sounds. There was no organomegaly or ascites. There was (+1) pitting edema in both lower limbs. The laboratory values were as follow:

WBC = 11000/mm³	PMN= 60%
lymph= 35%	Eos= 4%
Mono= 1%	Hemoglobin= 9.2 g/dl
MCV = 57 f.L	MCH=19.6
PlT = 201000/ mm³	AST = 34 u/L
ALT = 33 u/L	AlP = 251u/L
Bil (Total)= 0.6 mg/dl	Bil direct = 0.1 mg/dL
PT = 15 sec	PTT = 38 sec

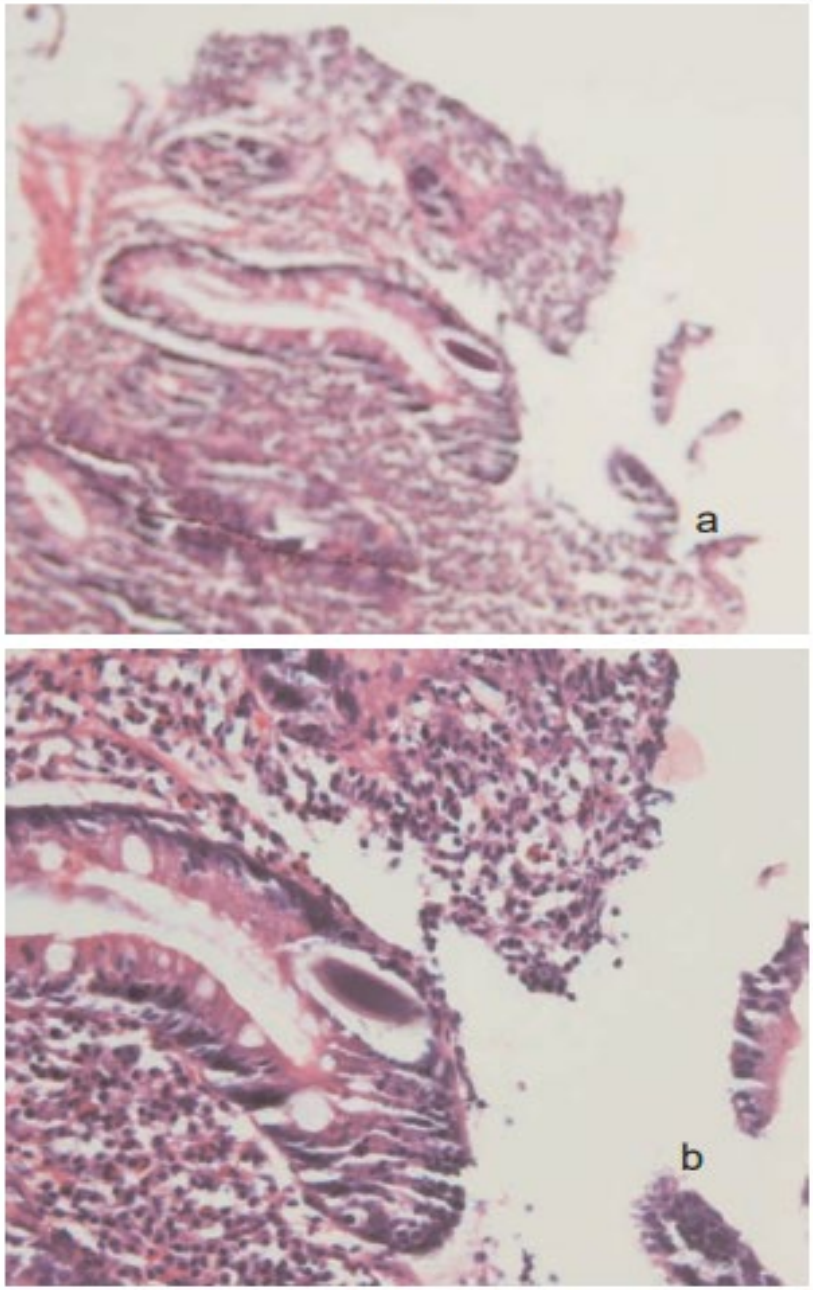

Fig. 1. Strongyloides larva in duodenal biopsy.

© Am J Case Rep, 2012; 13: 7-10

WWW.AMJCASEREP.COM
Case Report

Received: 2011.11.14
Accepted: 2012.01.10
Published: 2012.01.17

Gastric strongyloidiasis as multiple small gastric nodules

Afshin Shafaghi[1], Kurosh Askari[2], Hadi Hajizadeh[2], Fariborz Mansour-Ghanaei[1]

[1] Gastrointestinal and Liver Diseases Research Center (GLDRC), Rasht, Iran
[2] Guilan University of Medical Sciences, Rasht, Iran

Summary

Background: Strongyloidiasis, a common intestinal parasitic infection, is endemic in tropical and subtropical regions and occurs sporadically in temperate areas. It is endemic in Guilan province, Iran, and especially affects the rural population.

Case Report: We report the case of a 43-year-old woman living in Anzali (in the north of Iran), with dyspepsia and epigastric pain for 2 years, unresponsive to H2 receptor antagonists and proton pump inhibitors. Upper gastrointestinal endoscopy was done and showed multiple small nodules at the stomach. The pathologist reported *Strongyloides*. Treatment with Ivermectin and antibiotic triple therapy was done. She responded well to treatment and 6 months later an upper gastrointestinal endoscopy revealed no significant lesions and all nodules had disappeared.

Strongyloidiasis is usually not severe and frequently is nonspecific. For this reason, the infection is easily ignored by both the patients and physicians.

Conclusions: Although gastric involvement shows nonspecific symptoms, the possibility should be carefully considered by clinicians who practice in endemic areas.

key words: ***Strongyloides stercoralis*** • **stomach** • **strongyloidiasis**

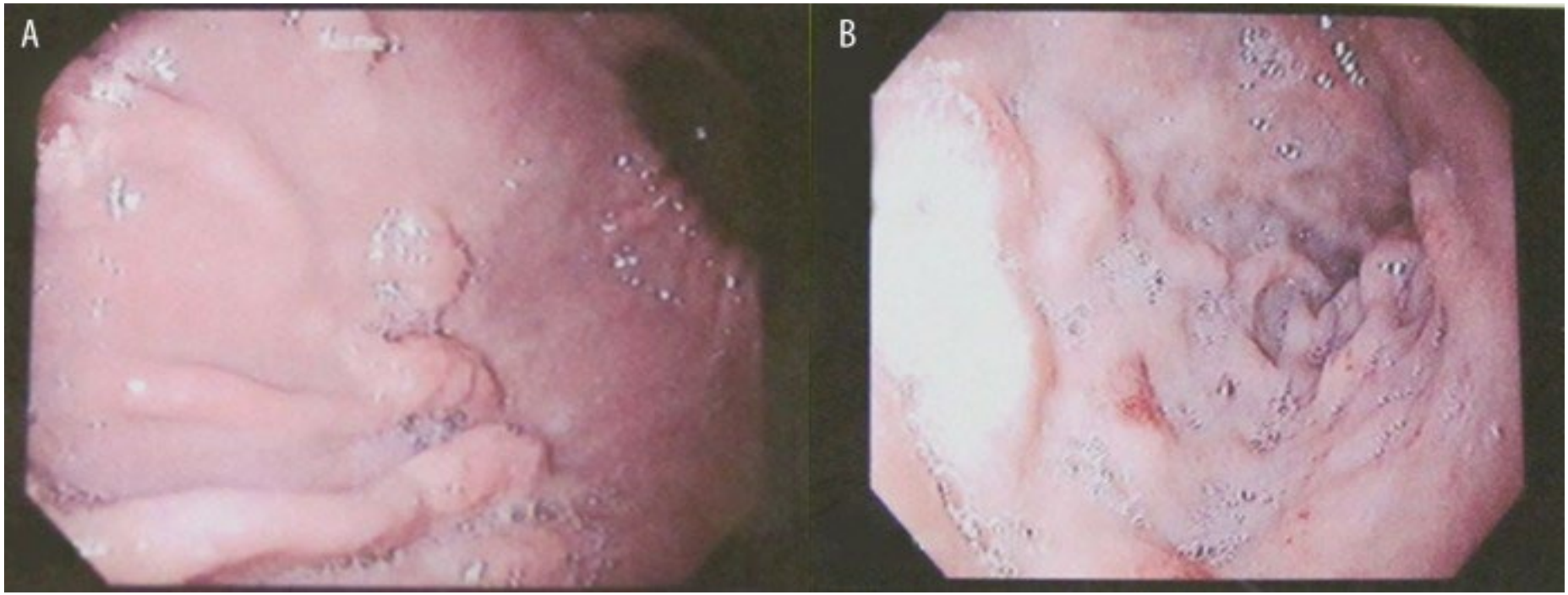
A
B

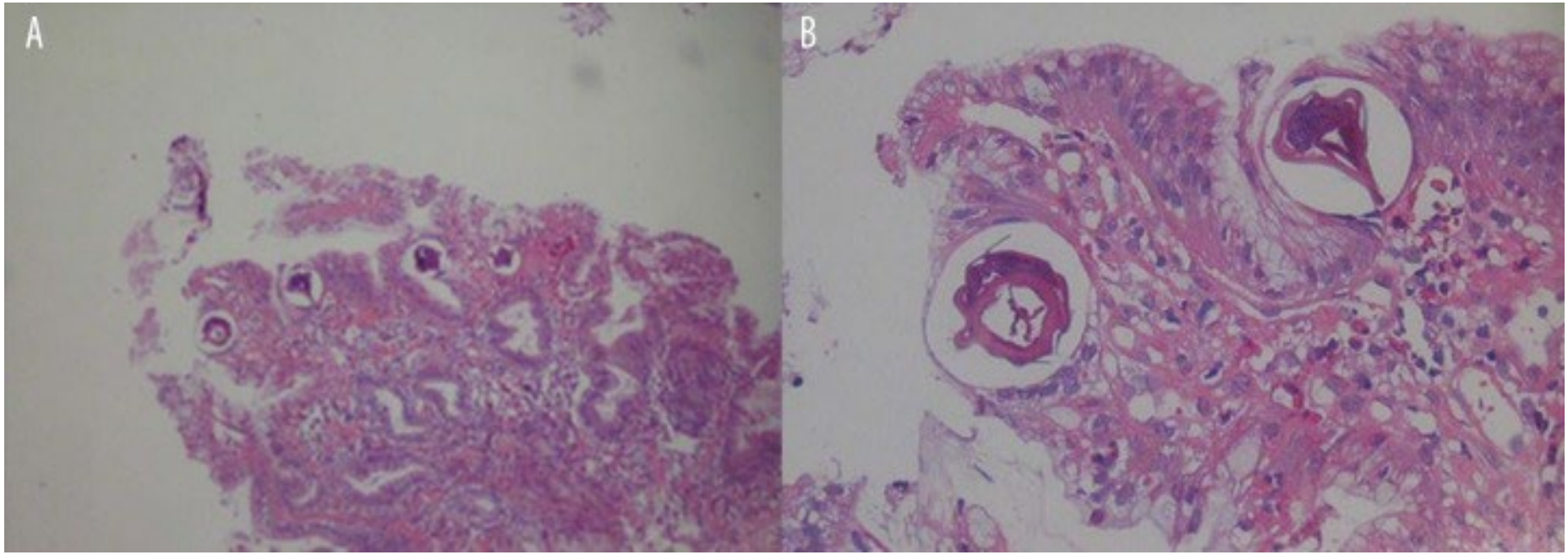
A
B

- **Respiratory symptoms** usually reflect the irritative responses related to the passage of larvae; these may include fever, dyspnea, cough, wheezing, choking, hoarseness, chest pain, hemoptysis, and palpitations . ARDS can occur during severe disease, usually in the setting of multiorgan failure. Chest radiographic imaging may demonstrate bilateral or focal interstitial infiltrates reflecting alveolar hemorrhage.

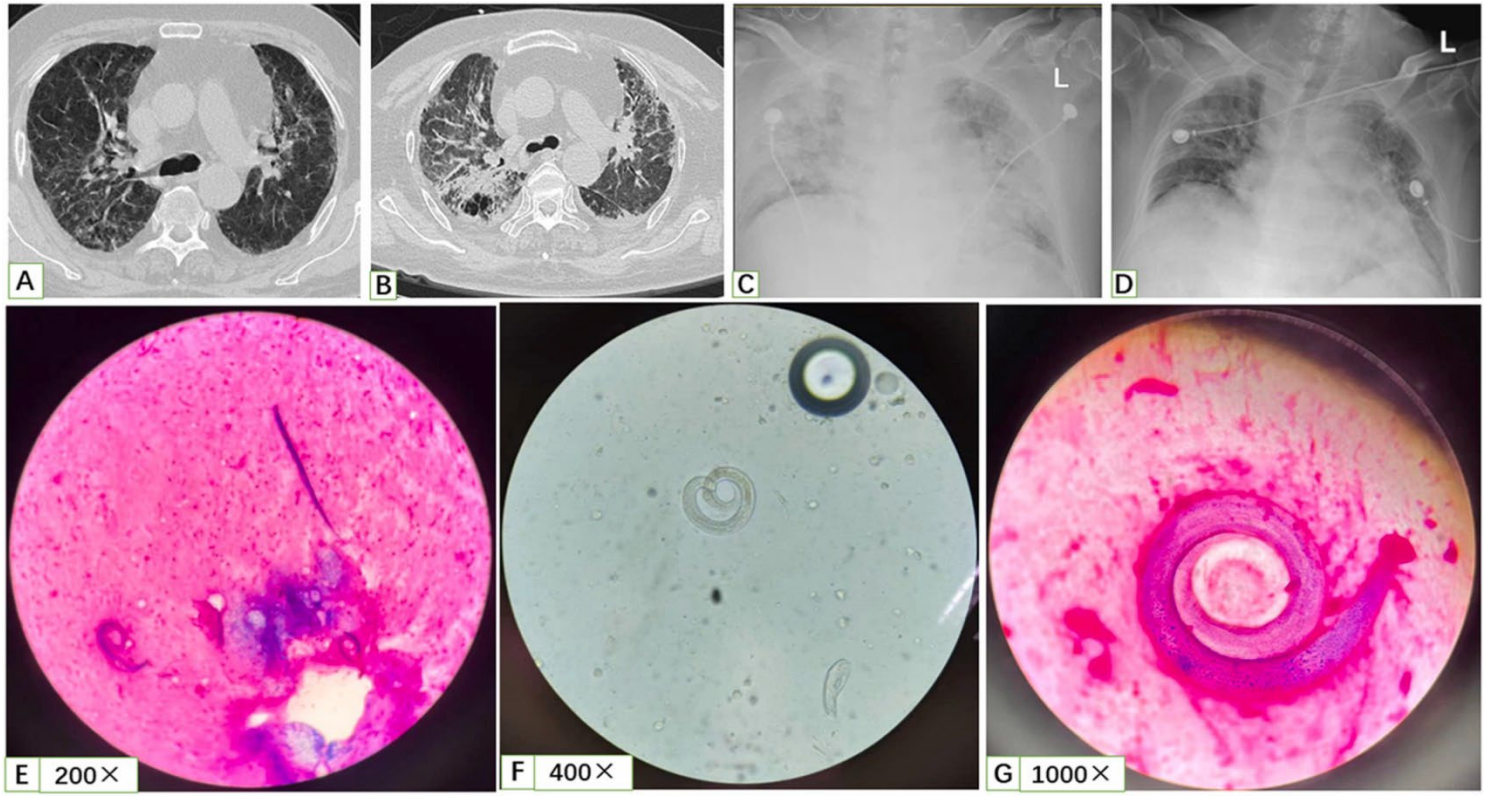

- **Dermatologic findings** include larva currens on the lower trunk, thighs, and buttocks. In addition, widespread petechial and purpuric lesions may develop. **Periumbilical purpura** may be a **pathognomonic** manifestation of **disseminated infection**; it refers to radiation of purpura from the umbilical area and resembles thumbprints .
- **Peripheral eosinophilia** is usually **absent** in the setting of hyperinfection and disseminated infection



2- Disseminated disease

- It was consisted of hyperinfection syndrome with spread of larvae to organs and tissues outside those in the autoinfection cycle; these may include the liver, gallbladder, pancreas, kidneys, ovaries, mesenteric lymph nodes, diaphragm, heart, brain, and skeletal muscle .

- Migration of filariform larvae during autoinfection may facilitate entry of enteric organisms into the systemic circulation.

- Clinically, this may manifest **as extraintestinal bacterial infection** such as pneumonia, meningitis, or sepsis; therefore, presence of fever and/or hemodynamic instability should prompt evaluation for systemic bacterial infection . In such cases, bacterial cultures (from the blood, sputum, spinal fluid, or other sites) may demonstrate enteric flora, and polymicrobial bacterial infection can occur.

Strongyloides stercoralis

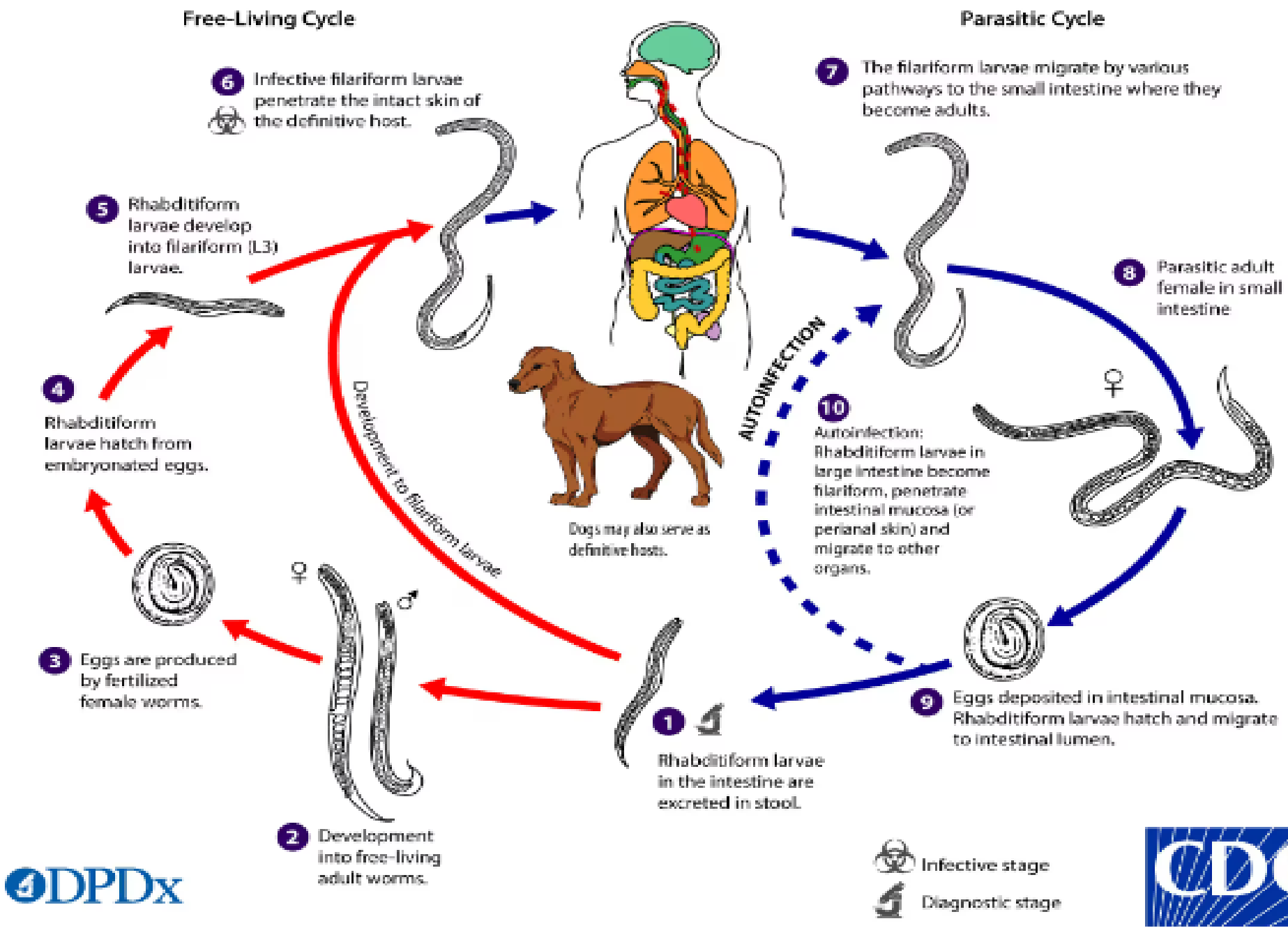

DPDx

CDC

29 April 2010

Disseminated strongyloidiasis following high-dose prednisolone administration

Afshin Shafaghi, *Kambiz Akhavan*, *Hadi Hajizade*, *Fariborz Mansour-Ghanaei*

Am J Case Rep 2010; 11:74-77 :: ID: 878549

Authors information > Article notes > Copyright and License information >

Abstract

Background: Strongyloides stercoralis is a common intestinal nematode that affects 30–100 million people worldwide. It is endemic in Guilan province and especially affects the rural population.

Case Report: We report the case of a 65-year-old woman living in Guilan province of Iran with a history of diabetes mellitus who was treated with high-dose prednisolone for temporal arteritis. Undiagnosed infestation by this nematode led to disseminated strongyloidiasis and Gram-negative sepsis. Fortunately, early diagnosis and prompt therapy with a proper anthelmintic drug as well as supportive care led to an acceptable outcome.

Conclusions: All patients who are candidates for immunosuppressive therapy or who are planned to receive steroid should be evaluated for strongyloidiasis. Although a stool exam is the first and simplest test for this purpose, it may be negative for the parasite despite a large parasitic burden. Thus physician awareness should be emphasized and a high index of suspicion required to diagnose this ominous condition by further evaluation (serology, evaluation of duodenal aspirate, and endoscopy with biopsy).

KEYWORDS: Strongyloidea, sepsis, immunosuppresion

